

بنام خدا






OCCUPATIONAL LUNG DISEASES

Seyed Mohammad Seyedmehdi


Occupational Medicine Specialist

Masih Daneshvari Hospital





EVALUATION OF PATIENTS WITH OCCUPATIONAL LUNG DISEASE

- (1) detailed history, including occupational and environmental exposures,
 - (2) thorough physical examination,
 - (3) appropriate imaging studies, and
 - (4) pulmonary function testing
- 



material safety data sheets (MSDS)

condition of the patient's home, any hobbies,
and social habits







Physical Examination

Occupational lung diseases do **not** present with specific clinical findings

It is difficult, for example, to distinguish asbestosis from idiopathic pulmonary fibrosis or chronic beryllium disease from sarcoidosis






The physical examination may be helpful if abnormal, but it is, in general, insensitive for detection of mild respiratory tract injury




Imaging Studies

A chest radiograph should be part of the workup when lung disease is suspected


However, normal radiographic findings do not exclude significant damage to the lung




Immediately after toxic inhalational injury, the chest radiograph frequently is normal




abnormal chest radiographs can be seen in individuals without significant lung injury who are exposed chronically to iron oxide or tin oxide



Abnormalities on the chest radiograph do not necessarily correlate with the degree of pulmonary impairment or disability



With dust-exposed persons, chest films should be interpreted according to the International Labour Organization (ILO) classification for pneumoconiosis, in addition to the routine interpretation




HRCT scanning is more sensitive than either conventional CT scanning or chest radiography for assessing the presence, character, and severity of a number of diffuse lung processes such as emphysema and interstitial lung disease

Pulmonary Function Testing

The most valuable of all pulmonary function parameters are those obtained from spirometry, namely, forced expiratory volume in 1 second (FEV_1), forced vital capacity (FVC), and the FEV_1/FVC ratio

presence and severity of airway obstruction



The forced expiratory flow from 25-75% of vital capacity (FEF_{25-75}) and the shape of the expiratory flow-volume curve are more sensitive indicators of mild airway obstruction


OCCUPATIONAL ASTHMA





OCCUPATIONAL ASTHMA

Asthma is characterized by airway obstruction that is reversible (but not completely so in some patients), either spontaneously or with treatment, airway inflammation, and increased airway responsiveness to a variety of stimuli




In occupational asthma, there is variable airway obstruction and/or airway hyper responsiveness as a consequence of workplace exposure(s)




OCCUPATIONAL ASTHMA

There are two major types of occupational asthma. Sensitizer-induced asthma is characterized by a variable time during which *sensitization* to an agent present in the work site takes place. Irritant-induced asthma occurs without a latent period after substantial exposure to an irritating dust, mist, vapor, or fume



The diagnosis of occupational asthma is made by confirming the diagnosis of asthma and by establishing a relationship between asthma and the work environment



The relationship between asthma and workplace exposure may fit any of the following patterns:

(1) symptoms occur only at work,

(2) symptoms improve on weekends or vacations,


(3) symptoms occur regularly after the work shift,

(4) symptoms increase progressively over the course of the work week, and


(5) symptoms improve after a change in the work environment




physical examination and Chest radiographs are normal in most individuals with asthma




spirometry for measurement of FEV₁ and FVC
is the most reliable method for assessing
airway obstruction







A 12% improvement in FEV₁ of at least 200 mL after inhaled bronchodilator is how the American Thoracic Society (ATS) defines a significant improvement indicative of hyper responsive airways




Across-work-shift spirometry, when available,
can provide objective evidence of
occupational asthma



A greater than 10% fall in FEV₁ across a work
shift is suggestive of an asthmatic response



Methacholine or histamine challenge can demonstrate the presence of nonspecific airway hyper responsiveness in a worker suspected of having occupational asthma who has normal spirometry



particularly valuable if it demonstrates an increase in airway responsiveness on returning to work or a decrease when away from work

***HYPERSENSITIVITY
PNEUMONITIS***






HYPERSENSITIVITY PNEUMONITIS

extrinsic allergic alveolitis





an immunologically mediated inflammatory disease of the lung parenchyma that is induced by inhalation of organic dusts that contain a variety of etiologic agents (e.g., bacteria, fungi, amebae, animal proteins, and several low-molecular-weight chemicals)




Diagnosis

acute or chronic presentation


The acute and more common form of presentation of hypersensitivity pneumonitis usually occurs within 4-6 hours of an intense exposure to the offending antigen



Symptoms : chills, fever, malaise, myalgia, cough, headache, and dyspnea




Physical examination :
relatively ill-appearing patient with bibasilar
inspiratory crackles on chest auscultation





Laboratory findings

Laboratory findings include peripheral blood leukocytosis with increased neutrophils and a relatively decreased lymphopenia







Chest radiographic findings

normal even in symptomatic individuals

Typically, the acute phase is associated with the presence of a reticulonodular pattern






Pulmonary function testing may reveal a decrease in the FEV₁ and FVC with an unchanged FEV₁/FVC ratio consistent with a restrictive impairment



A decrease in the DL_{co} reflecting impaired gas exchange also is typical of the acute presentation




Recurrent low-level exposure to an inappropriate antigen may result in the insidious onset of chronic interstitial lung disease with fibrosis



Treatment

avoidance of the offending antigen

Corticosteroids remain the mainstay of treatment of patients with severe or progressive hypersensitivity pneumonitis, despite the lack of controlled data regarding the effect of these agents on the disease process



Metal Fume Fever





Metal Fume Fever

an acute self-limiting flulike illness

The most common cause is the inhalation of zinc oxide




Treatment is entirely symptomatic



Polymer Fume Fever

A syndrome similar to metal fume fever may occur after inhalation of combustion products of polytetrafluoroethylene (Teflon) resins





Silicosis






Silicosis

a parenchymal lung disease that results from the inhalation of silicon dioxide, or silica





Exposure to silica can lead to one of three disease patterns:


(1) chronic simple silicosis, which usually follows more than 10 years of exposure to respirable dust with less than 30% quartz,

(2) subacute/accelerated silicosis, which generally follows shorter, heavier exposures (i.e., 2-5 years), and

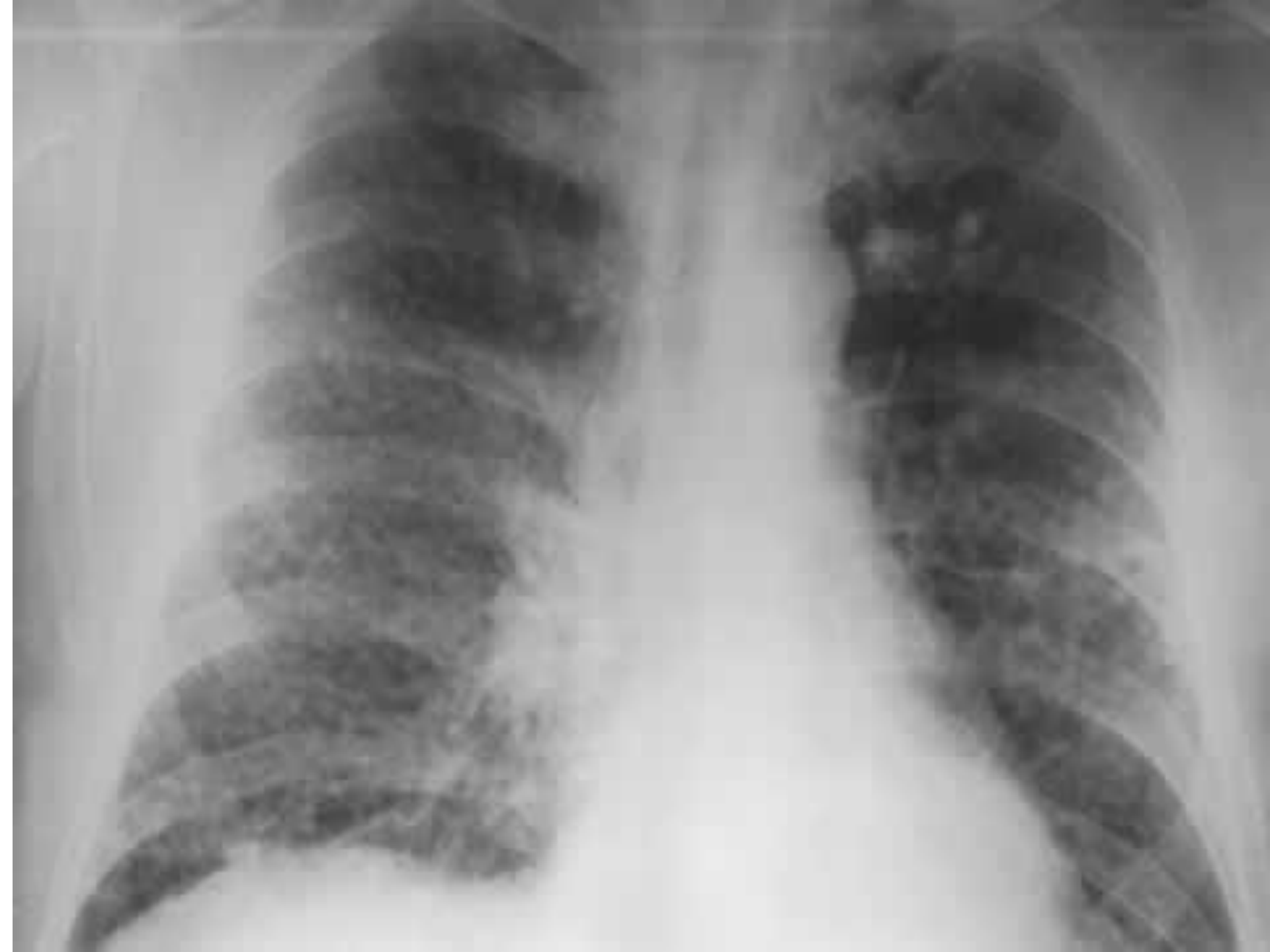(3) acute silicosis, which is seen often following intense exposure to fine dust of high silica content over a several month period

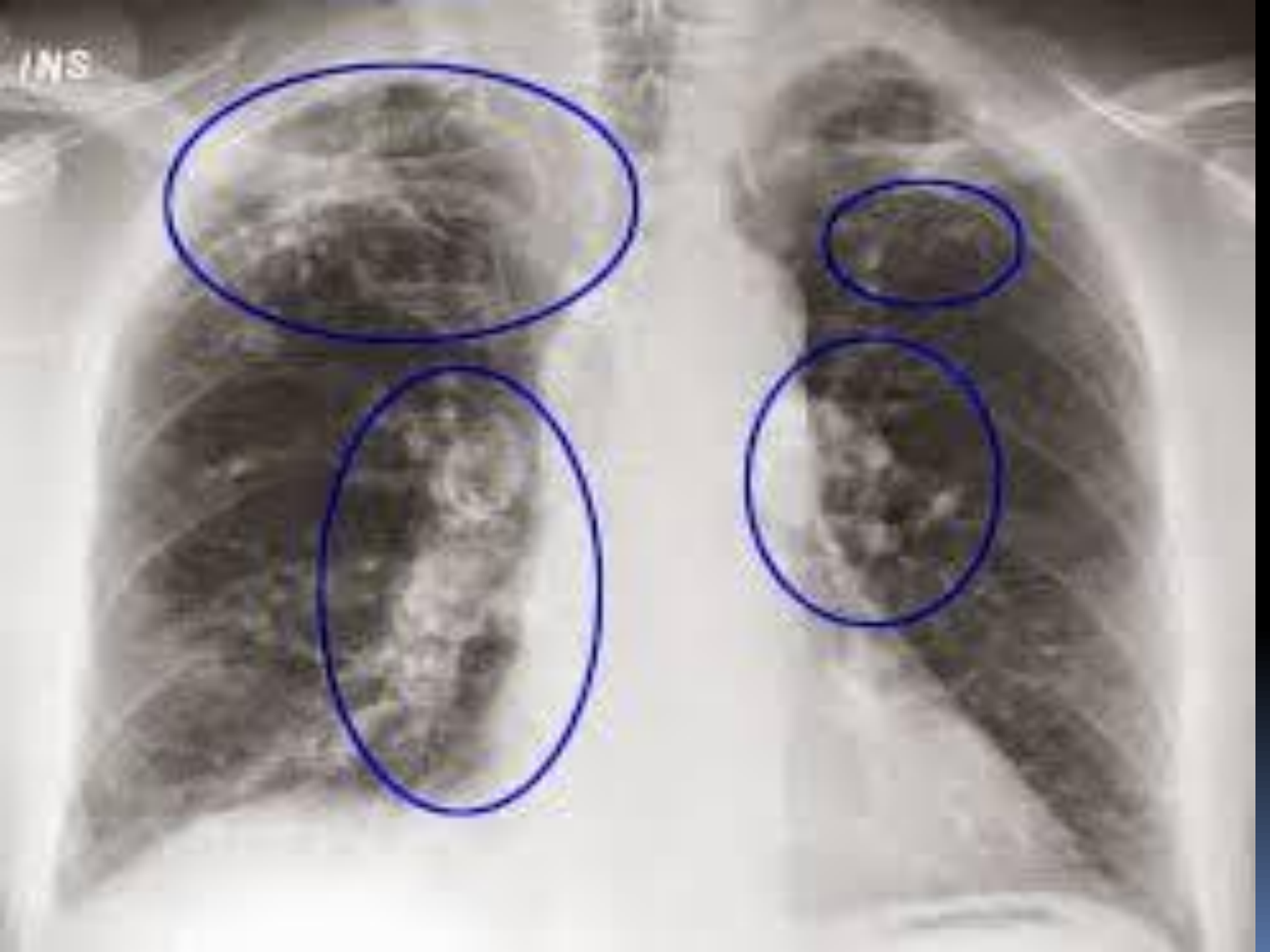


There are few symptoms and signs of chronic simple silicosis



The diagnosis usually is made by chest radiographs, which frequently reveal small round opacities (<10 mm in diameter) in both lungs, with a predilection for the upper lung zones









There is an increased incidence of mycobacterial disease, both typical and atypical


Fungal diseases (especially cryptococcosis, blastomycosis, and coccidioidomycosis) are also seen with greater frequency



management is directed toward the prevention of progression and the development of complications



The prognosis for patients with chronic silicosis is good, especially if they are removed from exposure



Mortality remains high, however, in those who develop PMF

A large, dense tree with many pink cherry blossoms against a clear blue sky. The tree's branches are thick and dark, and the blossoms are in full bloom, creating a thick canopy of pink. The sky is a pale, clear blue.

The
End

A
n
y
Q
u
e
s
t
i
o
n
?